

Human remains from Metsamor, Armenia, 2013–2021

Hasmik Simonyan¹, Krzysztof Jakubiak², Arkadiusz Sołtysiak^{*2}

¹ Department of Archaeology, History Museum of Armenia, Yerevan, RA, Republic Square 4, 010 Armenia

² Faculty of Archaeology, University of Warsaw, ul. Krakowskie Przedmieście 26/28, 00-927 Warszawa, Poland
email: a.soltysiak@uw.edu.pl (corresponding author)

The archaeological site of Metsamor is located in the Aras Valley near the modern village of Taronik ($40^{\circ}7'35''\text{N}$, $44^{\circ}11'17''\text{E}$, 852masl, about 35km south-west from Yerevan, the capital city of Armenia (**Figure 1**). The site dominates over the local landscape and at first glance it looks like a tell. The layout of the citadel, with monumental cyclopean walls, however, trace along the natural rocky hill edges. North of the citadel is the so-called lower town area where a Polish-Armenian team has conducted archaeological excavations since 2012 (Jakubiak & Piliposyan 2021). Fieldwork has focused on the settlement layout dated to the Iron Age periods I–III. Among the architectural remains, several human burials were unearthed. Generally, the chronological range of these human remains is relatively large. The oldest among the discovered bodies were dated to the late 8th or the beginning of the 7th century BCE.

The skeletons dated to that period were discovered buried in shallow graves. In these cases it was difficult to judge if they were intentionally dug out, or the dead

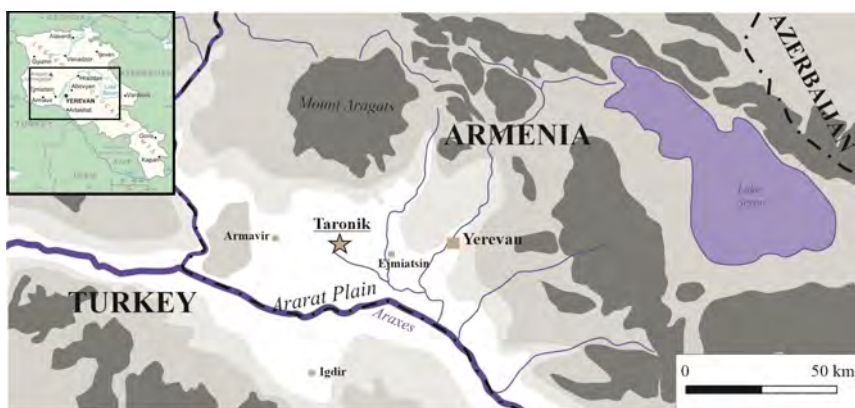

Figure 1. Map showing location of Metsamor. Drawing by M. Iskra.

bodies were covered with soil deposit only. The distribution of the skeletons on the streets or nearby the house entrance can be interpreted as the result of violent outbreaks that led to the abandonment of the settlement. The individuals associated with these possibly dramatic events were labeled as skeletons 2/2013, 3/2014, 7/2017 and 11/2019. These four skeletons discovered among the deposits manifested as ashy and burnt layers cannot be certainly associated with destruction of the entire town, but the distribution of the dead bodies makes this relation likely. The only real grave dated to this period (labeled as 11) was discovered under the floor of a large Urartian period house situated in the eastern part of the excavated area. A cylinder seal belonging to the buried individual was dated to the late 8th century BCE, which makes the burial relatively precisely dated.

The second episode, when burials appeared among the ruins of the abandoned settlement, is dated to the 2nd–3rd centuries CE. In that period the lower town area was turned into a graveyard. Usually, the dead bodies were buried in simple, very modest graves. The architectural remains, most probably still partly visible on the surface during the funeral ceremonies, were likely used as elements of grave structures. Therefore, the burials were located and then detected in the corners of the deserted and ruined buildings. Five such buildings have been unearthed and recorded during excavations to date, namely those labeled as 1/2013, 1/2015, 8/2018, 9/2018 and 13/2021.

The last category of graves includes a few burials similar to the previous ones in terms of the grave construction. The only elements that allow differentiation of this subset are the grave goods deposited inside the burial construction. In the case of the graves 10/2018 and 12/2021 it was possible to assess that the individuals were buried in the late 3rd or 4th century CE. It is still difficult to confirm that the area nowadays called the lower town was constantly used as the same necropolis between the 2nd and 4th centuries CE. The only undated individual is 6/2017, with no grave goods nor clear indicators of the grave construction.

Human remains from Metsamor are currently stored in the Service for the Protection of Historical Environment and Cultural Museum-Reservations. They were studied using a standard protocol (Buikstra & Ubelaker 1994) with some modifications (Sołtysiak et al. 2019). In total, twelve skeletons were excavated so far, all in individual graves (Table 1). They are often fairly complete and well preserved, although affected by some taphonomical agents, such as root etching and occasionally water-induced erosion. Only one skeleton (12/2021) was incomplete with a much poorer general state of preservation. Although solitary wasps were occasionally observed at the site, no insect tunnelling has been noted on the skeletal remains (cf. Pittoni 2009).

The collection includes mainly male individuals, although in such a small sample it is not possible to assess if this is a true sex distribution bias. However, the

Table 1. Basic description of human remains from Metsamor.
LEH – linear enamel hypoplasia.

No	Season	Sex	Age-at-death	Date	Caries	LEH	Comments
1	2013	F	40–50	2 nd -3 rd c. CE	2/10		abscess in RC* and LP1
2	2013	M	30–40	8 th -7 th c. BCE			
3	2014	M	30–40	8 th -7 th c. BCE			
1	2015	M	40–50	2 nd -3 rd c. CE			18 teeth lost ante-mortem
6	2017	M	40–50	?	0/11	++	initial DJD in some joints
7	2017	M	30–40	8 th -7 th c. BCE	1/25	–	
8	2018	M	30–40	2 nd -3 rd c. CE	7/25	–	
9	2018	–	9–11	2 nd -3 rd c. CE	0/10	+	caries in 3/9 deciduous teeth
10	2018	M	40–50	3 rd -4 th c. CE	5/19	–	fracture of left ulna; DJD in right femur
11	2019	F	30–40	8 th -7 th c. BCE	2/22	–	eburnation in both knee joints
12	2021	–	16–18	3 rd -4 th c. CE	0/15	+	
13	2021	F	30–40	2 nd -3 rd c. CE	2/14		healed skull fracture at right pterion

Table 1. Maximum diameters of the upper long bones and clavicles (in mm).

No	Clavicle		Humerus		Radius		Ulna	
	R	L	R	L	R	L	R	L
1	138.5	139.5	297	295	231	234	254	249
2			336		256		283	282
3				306	227	226	246	246
2015/1				321		257		274
6	158.5	155.0	337	325	251	246	270	
7	132.5		308	298	233	235	226	228
8	144.0	149.5	320	315	253	251	274	273
10	144.5	147.0	329	337	271	257	287	
11	135.0	143.0		302		229		252
13	120.5	122.5	255	250	206	204	226	223

age-at-death pattern is clearly biased, with no infants and younger children and only two subadult individuals. It may therefore be safely stated that the Lower Town at Metsamor was a burial place for adults and older subadults.

The prevalence of dental caries was relatively high, with only two per nine individuals unaffected by this condition. Linear enamel hypoplasia was noted in the canines of both subadult individuals (the younger of the two also exhibits evidence of *cribra orbitalia* with initial remodelling underway), but only in one adult. The relatively high frequency of dental caries and low frequency of LEH in adults suggests rather good living conditions, with diet abundant in sugars and low levels of stress.

Irrespective of temporal variability of the assemblage, bones of the upper extremity are usually asymmetrical, especially clavicles and humeri (Table 2), which suggests

high levels of activity beginning in childhood when the bones develop. Trauma was relatively rare at Metsamor, with only one small, healed depression fracture of a female skull (13/2021) and a completely healed fracture of the left ulna near its distal end in a male skeleton (10/2018), which was associated with deformation of the distal left radial metaphysis as well (Figure 2). The same individual suffered from advanced



Figure 2. Fracture of left ulna in individual 10/2018. Scale bar 1cm.



Figure 3. Degenerative joint disease in the femoral head of individual 10/2018.

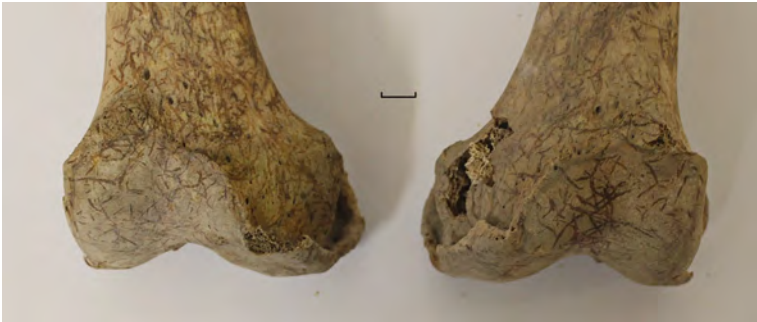

Figure 4. Degenerative joint disease in the knee joint of individual 11/2019. Scale bar 1cm.

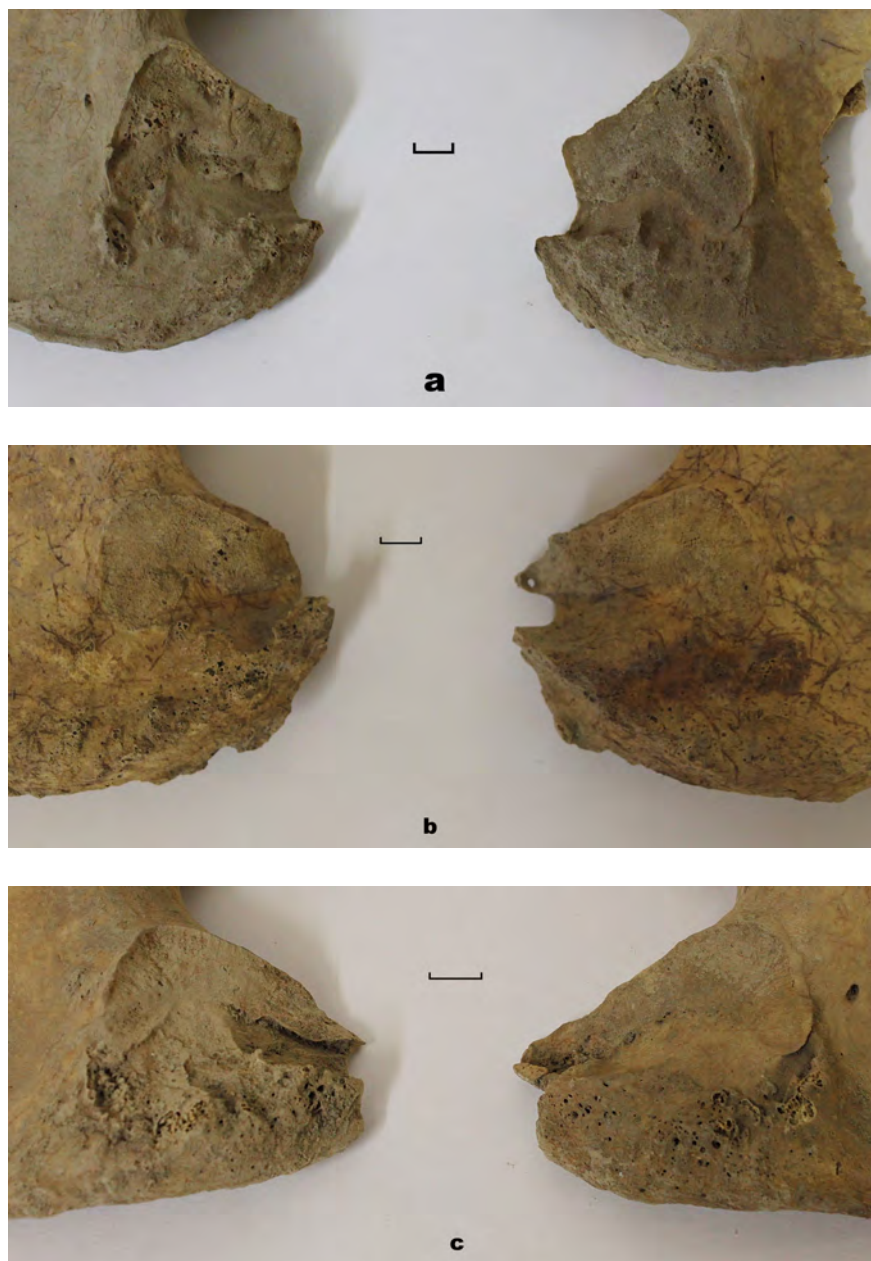


Figure 5. Auricular surfaces of three female individuals from Metsamor: (a) 1/2013, (b) 11/2019, (c) 13/2021. Scale bars 1cm.

degenerative joint disease in the right femoral head and acetabulum that may also have been the result of a trauma-related condition (Figure 3).

Initial degenerative joint disease was noted in all mature individuals, but more advanced stages have been observed in two females. One case of spondylosis of two cervical vertebrae (6th and 7th) was present in individual 13/2021, the same individual with cranial fracture. The female individual 11/2019 suffered from bilateral massive degenerative joint disease of the knee joint, with large osteophytes and eburnation at one condyle on both the right and left side (Figure 4).

The most interesting pathological conditions in the whole collection of human remains from Metsamor are, however, modifications of the auricular surface in all three females. The most advanced condition was observed in individual 11/2019, where very clear asymmetry occurred, with the right auricular surface extended distally, which was associated with osteophytes and porosity. A very similar pattern was noted in 13/2021, also with the right side affected, while in female 1/2013, degenerative joint disease was comparable on both sides (Figure 5). Such a pattern, especially in 11/2019 and 13/2021 suggests some kind of habitual activity that placed higher mechanical strain on the right innominate.

Acknowledgments: The project was financed by National Science Centre of Poland (grant 2018/29/B/HS3/01843). Many thanks are due to Dr. Ruzan Mkrtchyan, the supervisor and teacher of HS.

References

- Buikstra J.A., Ubelaker D.H. (eds.) (1994), *Standards for data collection from human skeletal remains*, Fayetteville: Arkansas Archaeological Survey.
- Jakubiak K., Piliposyan A. (2021), *The Metsamor Project: Results following six seasons of field excavations* [in:] “Archaeology of Armenia in regional context. Proceedings of the International Conference dedicated to the 60th Anniversary of the Institute of Archaeology and Ethnography held on July 9-11, 2019 in Yerevan”, P. Avetisyan, A. Bobokhian (eds.), Yerevan: Publishing House of the Institute of Archaeology and Ethnography, pp. 169–179.
- Pittoni E. (2009), *Necropoli of Pill'e Matta Quartucciu (Cagliari, Sardinia): Wild bee and solitary wasp activity and bone diagenetic factors*, *International Journal of Osteoarchaeology* 19(3):386–396.
- Sołtysiak A., Fazeli Nashli H., Safari M., Moradi G. (2019), *Human remains from Shahne Poshte, Iran, 2019*, *Bioarchaeology of the Near East* 13:85–96.